

## IMAGES IN CARDIOLOGY

### Successful Electrical Cardioversion of Long-Standing Persistent Atrial Fibrillation: Tips and Tricks

Antonis S. Manolis, MD\*, Theodore Kalos, MD

Athens University School of Medicine, Athens, Greece

\* E-mail: [asm@otenet.gr](mailto:asm@otenet.gr)

#### Abstract

A case of electrical cardioversion of long-standing persistent atrial fibrillation (AF) is presented along with tips and tricks for a successful strategy to restore and maintain sinus rhythm. *Rhythm* 2020; 15(3):52-54.

**Key Words:** long-term persistent atrial fibrillation; electrical cardioversion; antiarrhythmic drugs; anticoagulation

**Abbreviations:** AAD = antiarrhythmic drug; AF – atrial fibrillation; CV = cardioversion; ECG = electrocardiogram; LA = left atrium; OAC = oral anticoagulation; SR = sinus rhythm

An 87-year-old gentleman was seen as an outpatient because of concerns about fatiguability for over a year coinciding with the discovery of atrial fibrillation (AF) on a routine electrocardiogram (ECG) (**Fig. 1**). When AF was detected the patient was placed on anticoagulation therapy with apixaban 2.5 mg bid; apparently there was no need for rate control therapy as the ventricular response remained controlled without drugs. He had a history of prior pericardiectomy 30 years earlier for a “thickened” pericardium without further details being available. Thyroid function tests were within normal limits. Past medical history was otherwise unremarkable except for a known pre-diabetic status.

During this visit, the patient underwent an echocardiographic examination which showed a left ventricular ejection fraction of ~55% and left atrial (LA) enlargement (4.9 cm). He was subsequently scheduled for thallium scintigraphy which showed normal myocardial perfusion. The patient contemplated about having an initial attempt of sinus rhythm restoration by electrical cardioversion (CV), which he finally consented to belatedly at 4 months later. In preparation, he received propafenone 150 mg tid for a week prior to cardioversion. DC electrical cardioversion was finally performed with use of anteroposterior adhesive pads and deep sedation by administering 1.5 mg of midazolam and 30 mg of propofol. An initial attempt with 150 joules of biphasic synchronized electrical shock was unsuccessful, which was followed by a 270-joule shock that successfully restored sinus rhythm at ~80 bpm with a prolonged PR interval (**Fig. 2**). Patient was discharged home 3 hours later to continue receiving

oral anticoagulation therapy and rhythm control therapy with propafenone. One month later he remains in sinus rhythm.

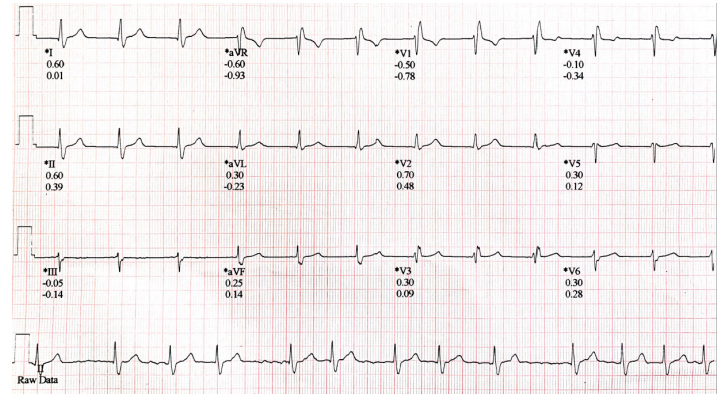


Figure 1

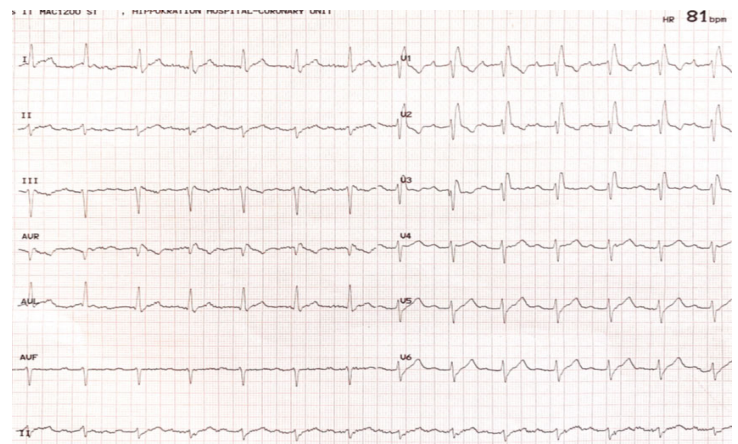


Figure 2



Although the issue of rhythm vs rate control of AF remains controversial, restoring and maintaining sinus rhythm (SR) may have its own inherent benefits.<sup>1</sup> In this context and sharing the view that at least one attempt of restoring SR in patients with first-detected AF would be worthwhile,<sup>1</sup> our elderly patient was advised to undergo electrical CV for his long-standing persistent AF.

In a large cohort study of 32,490 elderly patients with AF examining the overall frequencies of AF by type, persistent and long-standing persistent AF was present in 30%, while paroxysmal and permanent AF were present in 42% and 28% respectively.<sup>2</sup> More patients aged 75–79 years received rhythm control (44.2 %) vs rate control (38.8 %). Patients aged ≥85 years received either rate control therapy or no antiarrhythmic agent (~20 %, each). Significantly lower embolic and bleeding risk scores were observed in patients in the rhythm control group compared with the rate control group.

A recent large-cohort study of electrical CV in 1718 patients with long-standing persistent AF showed an 88.6% success rate and 0.5% complication rate.<sup>3</sup> Regarding the type of complications noted, 3 patients had minor stroke or transient ischemic attack (0.18%), and 5 patients had significant sinus node dysfunction requiring admission (0.29%). In this study, antiarrhythmic drugs (AADs) (amiodarone, dronedarone, sotalol, flecainide, and propafenone) had been administered in 96.5% of the patients at least 1 month before CV. Within 3 months, AF recurred in 55.5%.

### Tips and Tricks

Arrhythmia duration is a most important clinical variable that can limit the restoration of SR in patients with AF.<sup>4, 5</sup> The association of unsuccessful CV with AF duration may indicate atrial electrical and mechanical remodeling.<sup>5</sup> Patient's age does not seem to affect the result of CV.<sup>6</sup> Left atrial dimension >65 mm has been associated with AF recurrence, however use of antiarrhythmic drugs (AADs) and a short duration of AF before CV seem better predictors of maintenance of SR than echocardiographic measures of LA dimension.<sup>7</sup>

Difficulties in terms of limited success of external CV have been consistently reported in patients with persistent, especially long-standing persistent AF. To circumvent such difficulties the following measures and steps might facilitate and enhance successful CV and maintenance of SR.

- An *anteroposterior defibrillator paddle position* has been suggested as superior to an anterolateral location with regard to technical success in external cardioversion of stable AF.<sup>8</sup> This is precisely the technique that we have been using in AF patients and employed in the present case. The provision should be to place the pads in positions (left parasternal for the anterior pad and left infrascapular/paravertebral position for the posterior pad) that will include the LA between them and thus the electrical current will successfully defibrillate this chamber. When an anterolateral position is chosen with one pad placed in the right infraclavicular area, the other pad should be placed in a most postero-lateral axillary position, as possible, rather than an apical position, again so that the LA may be included in the field and direction of the electrical current that is delivered. *Biphasic shocks* are always preferable as proven to be more effective than monophasic shocks.<sup>9</sup>

- *Prophylactic rhythm control AAD therapy* should have been established before the scheduled CV procedure.<sup>9</sup> This entails commencement of the AAD when it is safe to do so, i.e. after the patient has received OAC therapy for at

least 3-4 weeks. The CV procedure should be delayed for at least an additional week of AAD therapy so that a steady state of the AAD has been achieved. Note that 95% of the steady state of AAD having a half-life of 15-20 hours (e.g. propafenone, flecainide) is reached after 5 half-lives, i.e. 3-4 days; however, it would be better if >99% of the steady state has been achieved, hence the wait for  $\geq 1$  week before performing CV. The exception relates to amiodarone, which when chosen as rhythm control and prophylaxis of AF recurrences, it should have been given in moderate doses (e.g. 200 mg bid) for at least 2 weeks before CV; after CV, amiodarone could be continued for another 1-2 weeks at the same dose and then reduced to 200 mg qd. AADs, when used together with electrical CV, help facilitate achieving persistent SR in patients who have immediate recurrence of AF (IRAF), i.e. successful CV to SR, for even just one beat, followed by recurrence of AF within minutes, and in those who truly fail CV with no restoration of SR at all.<sup>10</sup>

- *Deep sedation achieved via small-dose anesthetic use* is required for transthoracic electrical CV. Hence, the procedure is always performed in a *fasting state*, i.e. nothing by mouth (NPO) for at least 6-8 hours, for the risk of vomiting and ensuing aspiration of gastric contents. When using small doses of short-acting agents, brief deep sedation is achieved, patients' respiration is not compromised and thus patients may be discharged within hours after recovery from anesthesia. We choose a small dose of midazolam (only 1-2 mg) for the purpose of facilitating sedation but mostly for the retrograde amnesia it provides in case that the patient is not deeply sedated and feels some discomfort during CV. We combine this with small doses (aliquots) of propofol (20-30 mg) which may induce deep sedation and one may repeat in few minute-intervals, if needed, and thus achieve short-lasting deep sedation. In cases where repeat CV attempts are needed, repeat small doses of propofol will have the desirable sedative effect, again without compromising respiration. With this technique one may lessen the need to use a benzodiazepine antagonist such as flumazenil (anexate) with its attendant side-effects (e.g. convulsions).

- *Nasal oxygen/vital sign monitoring.* During the CV procedure, the patient should be on a nasal cannula of O<sub>2</sub> at  $\geq 4$ -5 L/min; an IV line should have been in place beforehand and heart rhythm, blood pressure and oximetry monitored throughout the procedure.

- *Head up / Chin lift maneuver.* The patient could be lying flat in a supine position without a pillow and preferably a head-up/chin lift maneuver applied to maintain the airway open; otherwise, this or the jaw thrust maneuver should be

applied promptly when the patient is noted to start snoring indicating upper airway obstruction.

- When SR is restored, the patient can be awakened and speech and limb movements checked to assess neurological status.

- If SR is not maintained and after a few beats AF recurrence (IRAF) is noted, one can decide whether to repeat the CV later (e.g. at 20-30 min), but only after administering additional AAD rhythm control therapy, e.g. with IV procainamide or amiodarone. Immediate AF recurrence may occasionally indicate inadequate prior AAD drug therapy and need for additional dosing, rather than refractory arrhythmia. When frequent atrial premature complexes (APCs) are noted right after successful CV, similarly, there may be an indication of needing additional AAD dosing; others have suggested a higher AF recurrence rate when this happens.<sup>11</sup>

- After successful CV, the patient needs to be closely monitored for a few hours and not allowed to fall asleep for the risk of compromised respiration and also for the risk of aspiration.

- The need for adequate pre- and post-procedural continuation of oral anticoagulation (OAC) therapy cannot be emphasized enough; OAC is needed for at least 3-4 weeks prior to and for 1 month after CV and continued thereafter according to the CHA<sub>2</sub>DS<sub>2</sub>VASc score.<sup>12</sup>

When all these suggested approaches are carefully implemented, external DC CV is highly successful in restoring SR and maintaining it at least for a while and there is virtually no need to resort to internal CV as it had been suggested in the past.<sup>13</sup> Regarding successful maintenance of SR, this depends on several other factors, among which, associated comorbidities and the extent of structural remodeling seem to play an important role.<sup>14, 15</sup>

## References

1. Manolis AS. Rhythm or Rate Control Management of Atrial Fibrillation: An Overrated Dilemma. *Hellenic J Cardiol* 2015;56:495-500.
2. Yuzawa H, Inoue H, Yamashita T, et al. Rhythm versus rate control strategies regarding anticoagulant use in elderly non-valvular atrial fibrillation patients: Subanalysis of the ANAFIE (All Nippon AF In the Elderly) Registry. *J Cardiol* 2020.
3. Son NKL, Park JW, Kim M, et al. Efficacy and Safety of Outpatient Clinic-based Elective External Electrical Cardioversion in Patients with Atrial Fibrillation. *Korean Circ J* 2020;50:511-23.
4. Frick M, Frykman V, Jensen-Urstad M, Ostergren J, Rosenqvist M. Factors predicting success rate and recurrence of atrial fibrillation after first electrical cardioversion in patients with persistent atrial fibrillation. *Clin Cardiol* 2001;24:238-44.
5. Elhendy A, Gentile F, Khandheria BK, et al. Predictors of unsuccessful electrical cardioversion in atrial fibrillation. *Am J Cardiol* 2002;89:83-6.
6. Fumagalli S, Boncinelli L, Bondi E, et al. Does advanced age affect the immediate and long-term results of direct-current external cardioversion of atrial fibrillation? *J Am Geriatr Soc* 2002;50:1192-7.
7. Volgman AS, Soble JS, Neumann A, et al. Effect of left atrial size on recurrence of atrial fibrillation after electrical cardioversion: atrial dimension versus volume. *Am J Card Imaging* 1996;10:261-5.
8. Botto GL, Politi A, Bonini W, Broffoni T, Bonatti R. External cardioversion of atrial fibrillation: role of paddle position on technical efficacy and energy requirements. *Heart* 1999;82:726-30.
9. Joglar JA, Kowal RC. Electrical cardioversion of atrial fibrillation. *Cardiol Clin* 2004;22:101-11.
10. Kim SS, Knight BP. Electrical and pharmacologic cardioversion for atrial fibrillation. *Med Clin North Am* 2008;92:101-20, xi.
11. Maounis T, Kyrozi E, Katsaros K, et al. The prognostic significance of atrial arrhythmias recorded early after cardioversion for atrial fibrillation. *Pacing Clin Electrophysiol* 2001;24: 1076-81.
12. Kirchhof P, Benussi S, Kotecha D, et al. 2016 ESC Guidelines for the management of atrial fibrillation developed in collaboration with EACTS: The Task Force for the management of atrial fibrillation of the European Society of Cardiology (ESC) Developed with the special contribution of the European Heart Rhythm Association (EHRA) of the ESC Endorsed by the European Stroke Organisation (ESO). *Eur Heart J* 2016;37:2893-962.
13. Lévy S, Lauribe P, Dolla E, et al. A randomized comparison of external and internal cardioversion of chronic atrial fibrillation. *Circulation* 1992;86:1415-20.
14. Jahangir A, Lee V, Friedman PA, et al. Long-term progression and outcomes with aging in patients with lone atrial fibrillation: a 30-year follow-up study. *Circulation* 2007;115:3050-6.
15. Schoonderwoerd BA, Van Gelder IC, Van Veldhuisen DJ, Van den Berg MP, Crijns HJ. Electrical and structural remodeling: role in the genesis and maintenance of atrial fibrillation. *Prog Cardiovasc Dis* 2005;48:153-68.